New Diagnostic Modalities for Assessing Skeletal Effects of Glucocorticoids

Giuseppe Guglielmi
Department of Radiology
University of Foggia
Scientific Hospital "Casa Sollievo della Sofferenza"
San Giovanni Rotondo - Foggia

Introduction

Glucocorticoid (GC) treatment is widely used among the adult population for a variety of inflammatory conditions and is considered the most common cause of secondary osteoporosis among this population. Patients chronically treated with GCs often suffer from significant trabecular bone loss with changes in bone microarchitecture which contribute to the increase in fracture risk.

Introduction

Dual-energy X-ray Absorptiometry (DXA) is the gold standard method used to evaluate bone mineral density (BMD), however, quantitative computed tomography (QCT) has also been used to evaluate density of trabecular or cortical bone and total BMD, as a surrogate to measure bone strength, providing data about risk fracture.

RADIOGRAPHIC FEATURES

- Conventional radiology is useful to grossly quantify bone density and microstructural changes. However, approximately **20-40%** of bone mass has to be lost for a bone to appear osteopenic, which means that diagnosis from radiographs is always going to be **late**.

- Technical factors can affect the appearance of bone.
- Inter-observer agreement not good.

Diagnosis of Vertebral Fracture

Clinical diagnosis misses of vertebral fractures 67% - 75%

Radiologic diagnosis misses of vertebral fractures 27% - 85%

Sensitivity of axial CT images to detect vertebral fracture = 0.35

--Importance of sagittal reformats--

Williams AL et al. Underreporting of osteoporotic vertebral fractures on computed tomography. Eur J Radiol. 2009 Jan;69(1):179-83.

Spinal Radiographs

- Are used to detect vertebral deformities
- Play a key role in establishing the efficacy of drugs in osteoporosis treatment and prevention trials
- Have to be interpreted with expert knowledge of anatomy and pathology

Radiologic Diagnosis

Based on qualitative impression

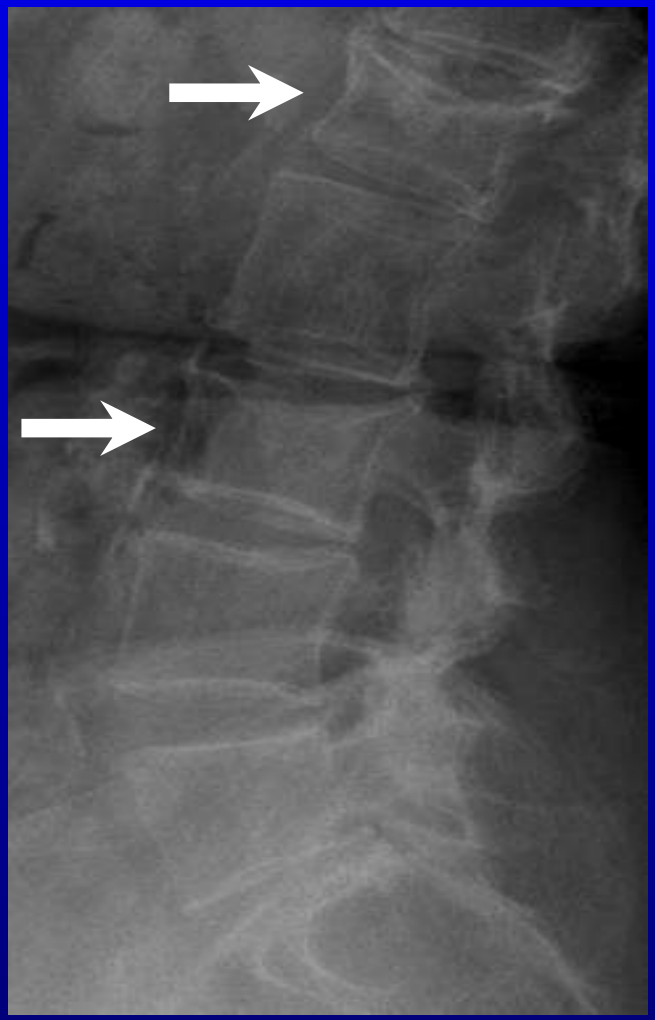

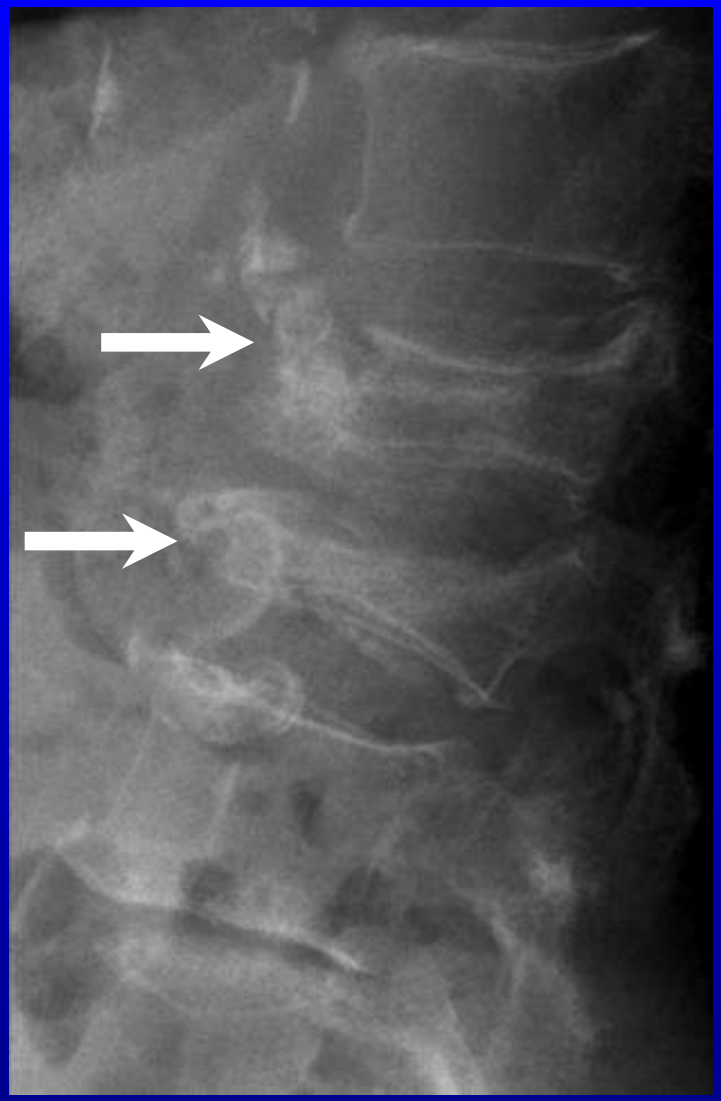

Loss of anterior, middle, or posterior height that exceeds 20% is a fracture

Borderline Vertebral Fractures

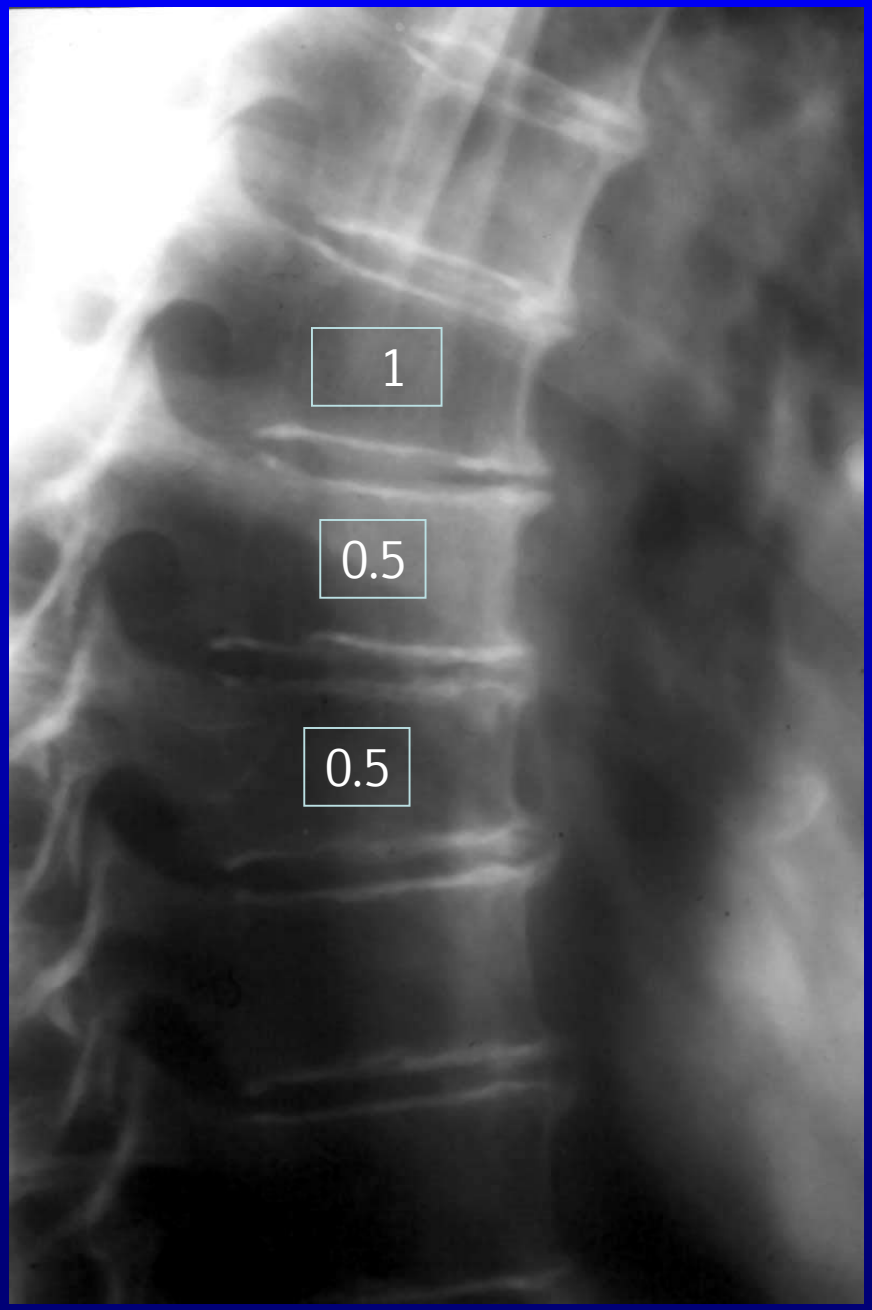

Semiquantitative visual grading of vertebral fractures

Normal
(Grade 0)

Wedge fracture | Biconcave fracture | Crush fracture

Mild fracture
(Grade 1, ~20-25%)

Moderate fracture
(Grade 2, ~25-40%)

Severe fracture
(Grade 3, ~40%)

Genant & Wu, Osteoporos Int (1993)

Morphometry with Six-Point Placements

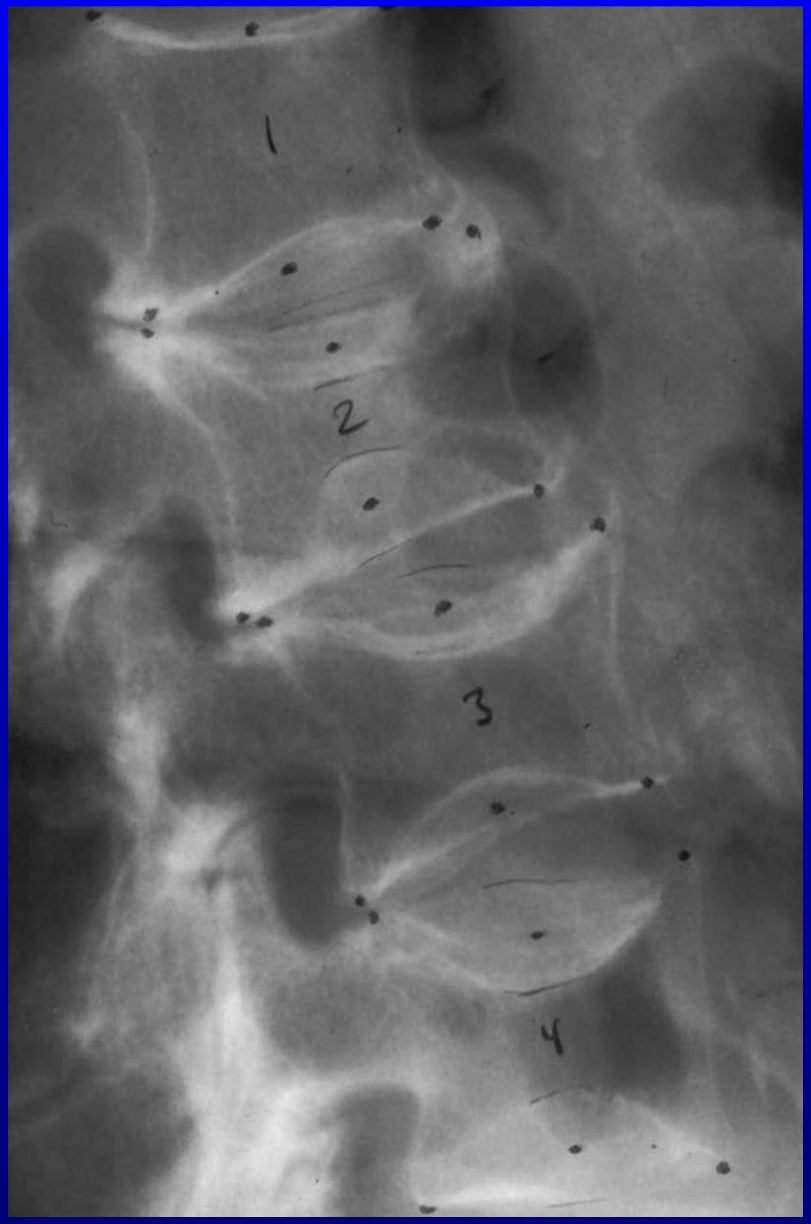

Computer Aided Diagnosis
X–ray

- X-ray scoring and measurement methods have been developed and validated for musculoskeletal clinical trials.
- Software tools are being developed to help with the reproducibility and speed of these manual methods.
- These tools may be useful in clinical point-of-care X-ray reporting.
- More information may be extracted from X-ray images by shape or texture analysis that may produce CAD software tools in the future.

6 Point Quantitative Morphometry

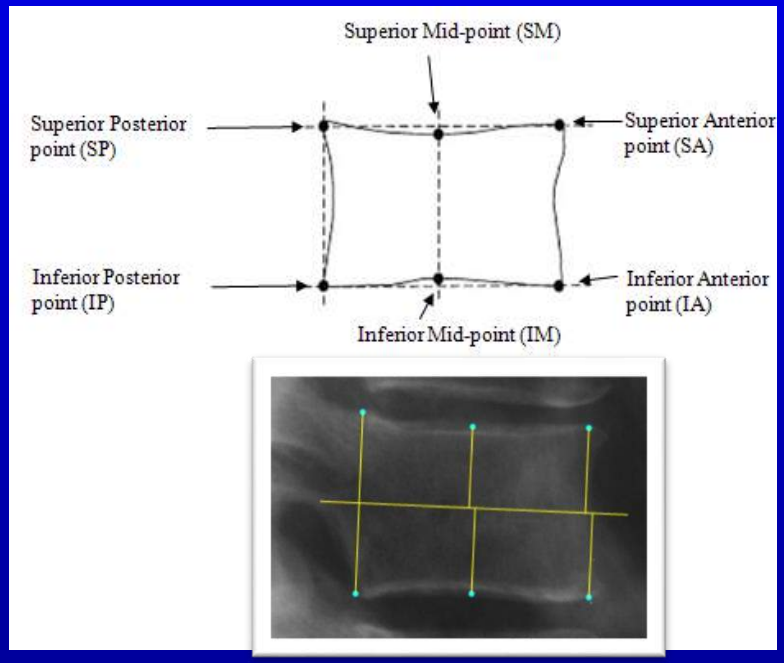

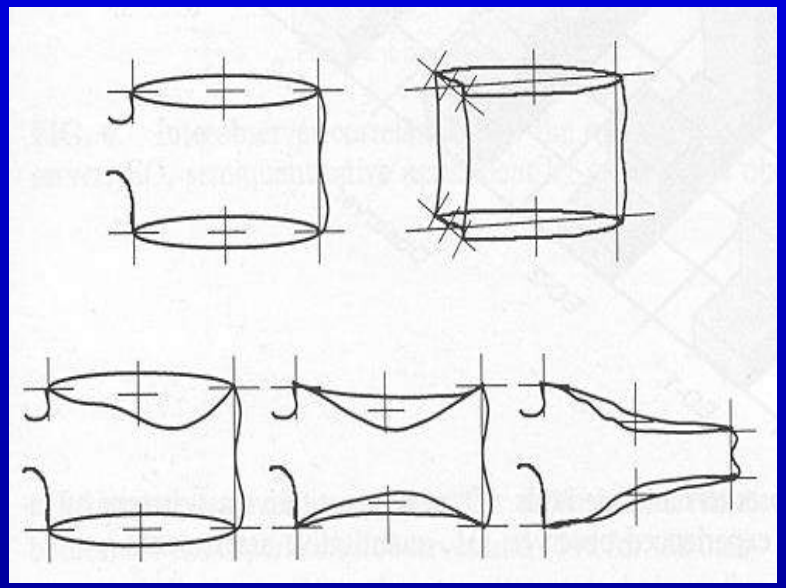

6 points placed on the projection of each vertebral body. Three height measurements used to determine normal shape: wedge, biconcave or crush deformities.

A Full Vertebral Shape Description

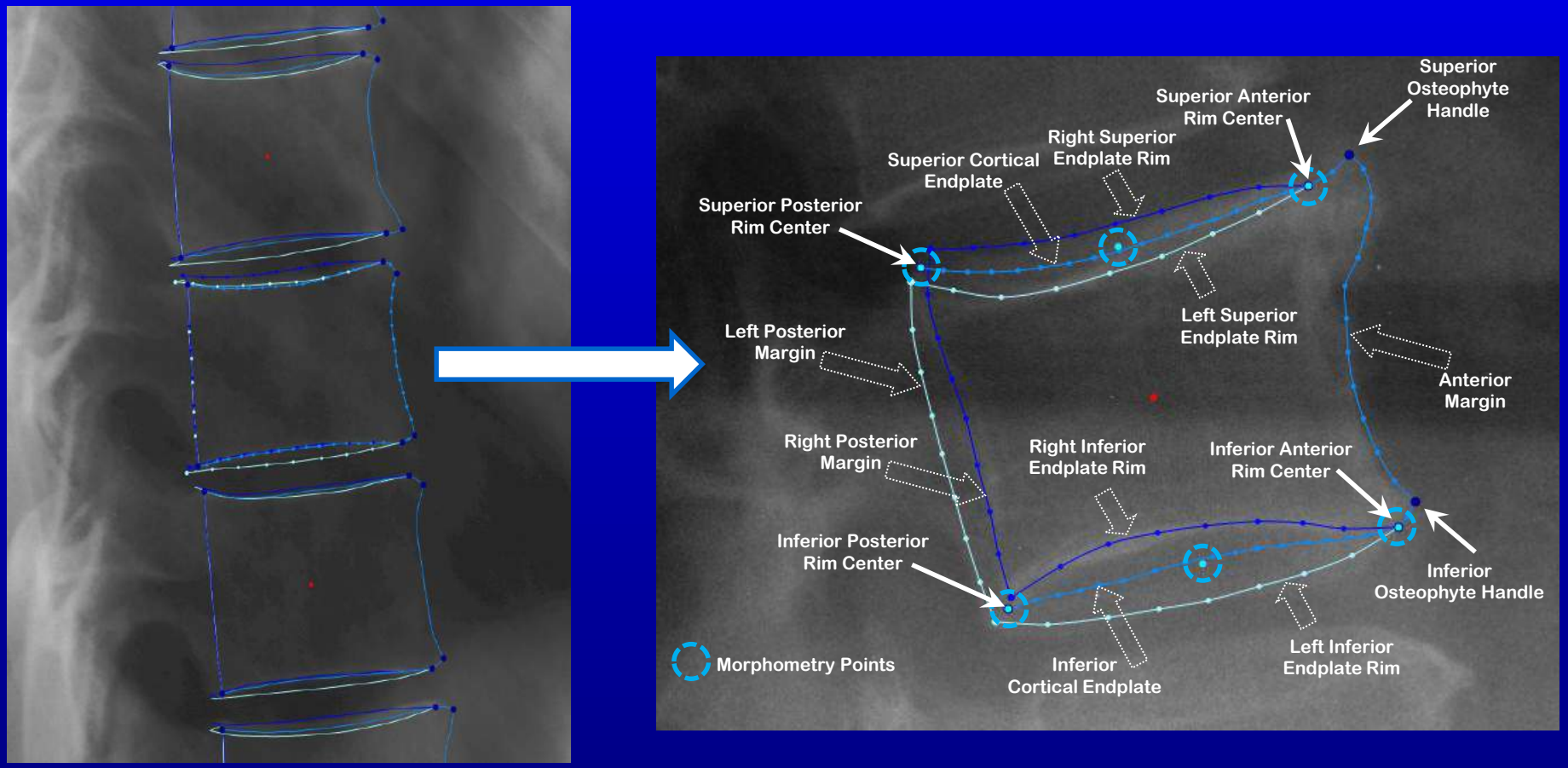

Semi-automated quantitative morphometry on X-ray

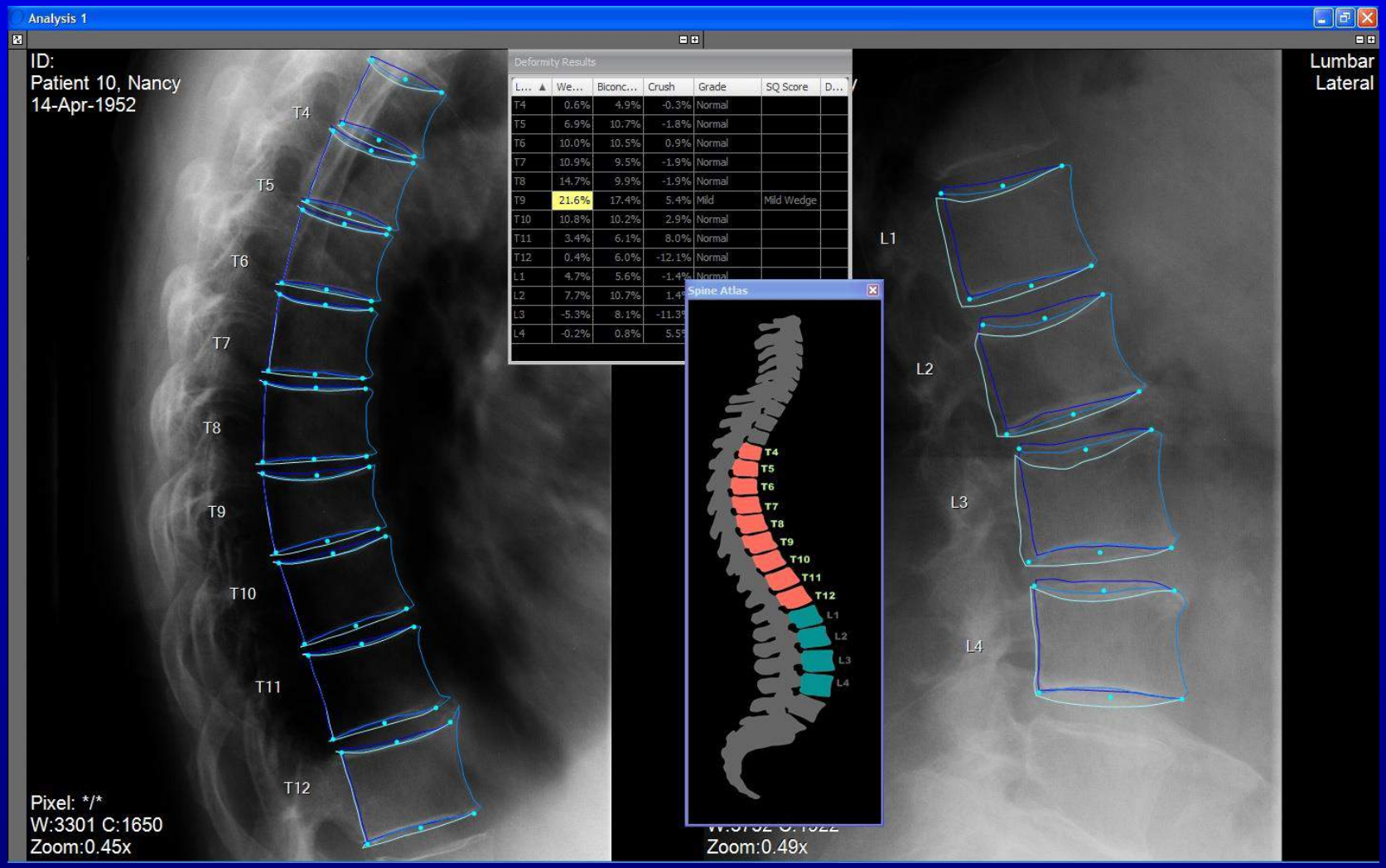

Review and Adjustment

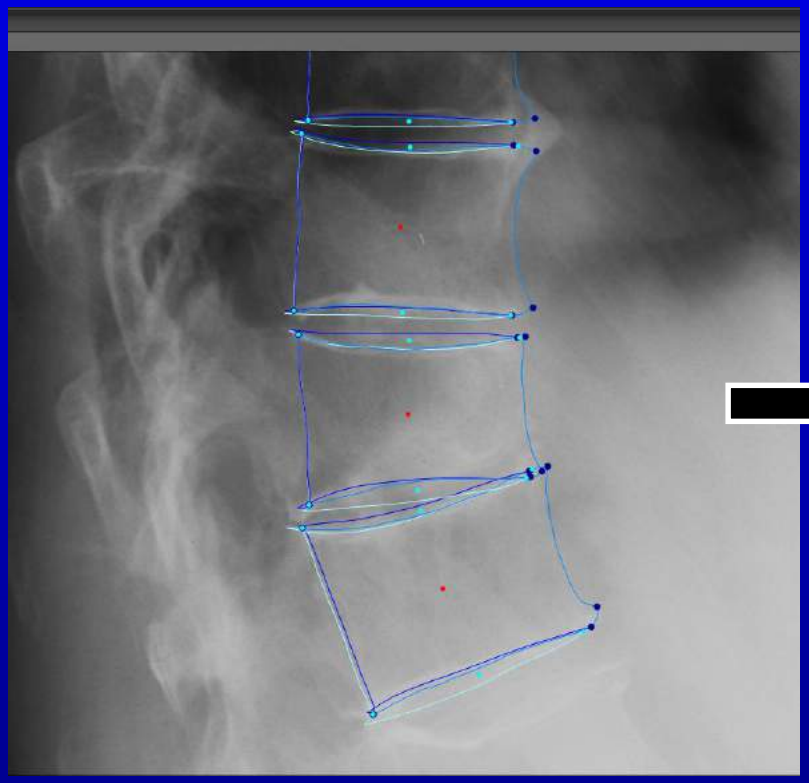

User review

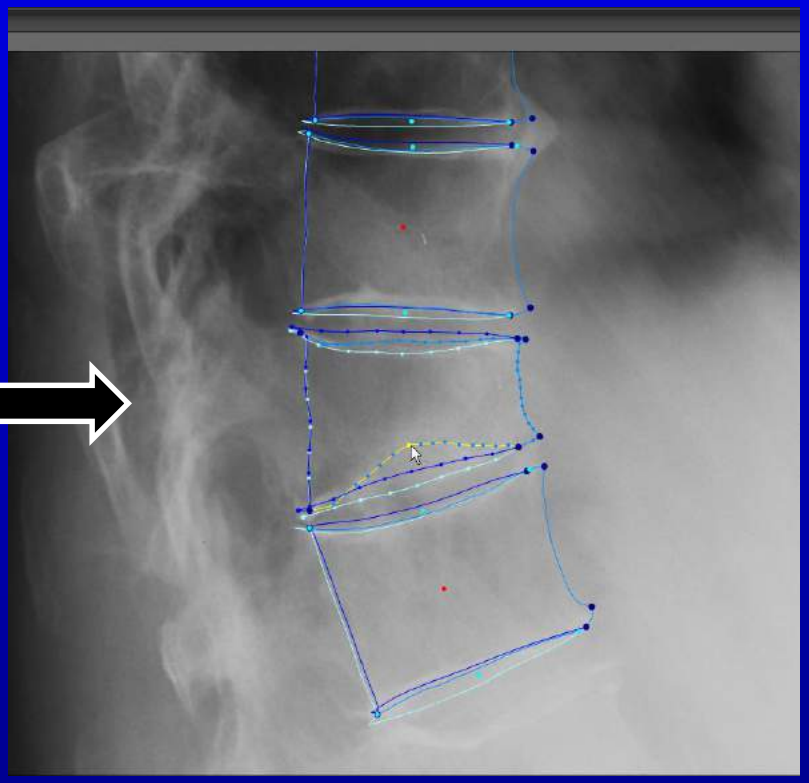

Adjust contours (and 6 point positions) if necessary

Deformity Results

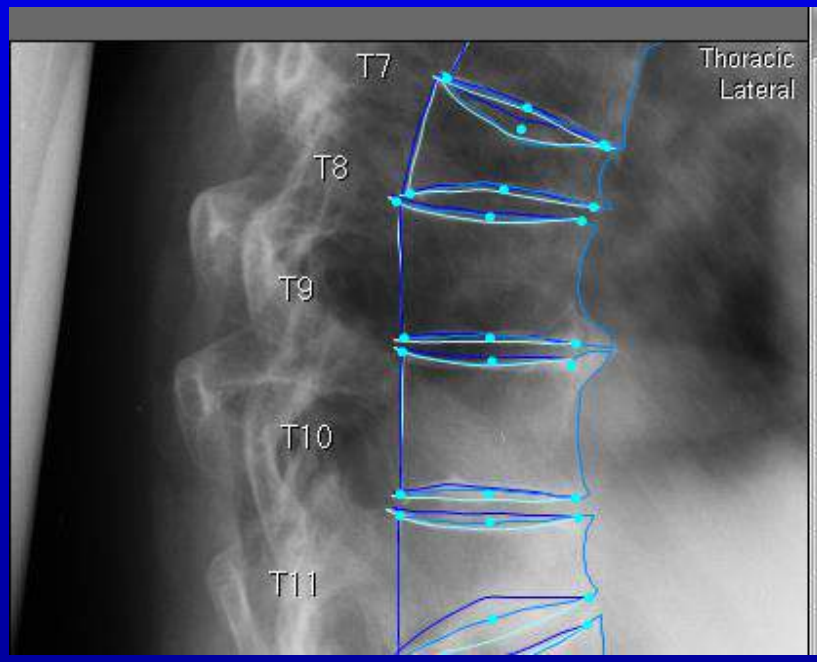

Deformity Results

Level	Wedge	Biconc...	Crush	Grade	SQ Sc...
T4	25.4%	21.9%	7.8%	Moderate	Mild W...
T5	5.5%	2.2%	-37.5%	Normal	
T6	36.4%	32.0%	13.0%	Moderate	Moder...
T7	7.5%	10.4%	-67.2%	Normal	
T8	49.2%	49.3%	10.2%	Severe	Severe...
T9	9.6%	11.0%	4.7%	Normal	
T10	6.4%	6.7%	-8.8%	Normal	
T11	43.3%	32.8%	12.8%	Severe	Severe...
T12	14.5%	14.4%	-73.0%	Normal	
L1	30.3%	21.7%	6.3%	Moderate	Moder...
L2	-3.7%	7.0%	-1.5%	Normal	
L3	-0.1%	8.6%	-2.0%	Normal	
L4	-5.4%	6.5%	-3.3%	Normal	

- Height ratios define deformity types
  - wedge, biconcave, crush.
- Height ratio thresholds define deformity severities:
  - Normal , mild (>20%), moderate (25%), severe (>40%).

VFA

2015 Adult Official Positions

Indications

- Lateral Spine imaging with Standard Radiography or Densitometric VFA is indicated when T-score is < -1.0 and of one or more of the following is present:
- Women age ≥ 70 years or men ≥ age 80 years
- Historical height loss > 4 cm (>1.5 inches)
- Self-reported but undocumented prior vertebral fracture
- Glucocorticoid therapy equivalent to ≥ 5 mg of prednisone or equivalent per day for ≥ 3 months

VFA
Vertebral Fracture Assessment

Densitometric spine imaging performed for the purpose of detecting vertebral fractures.

Dual-energy X-ray Absorptiometry (DXA)

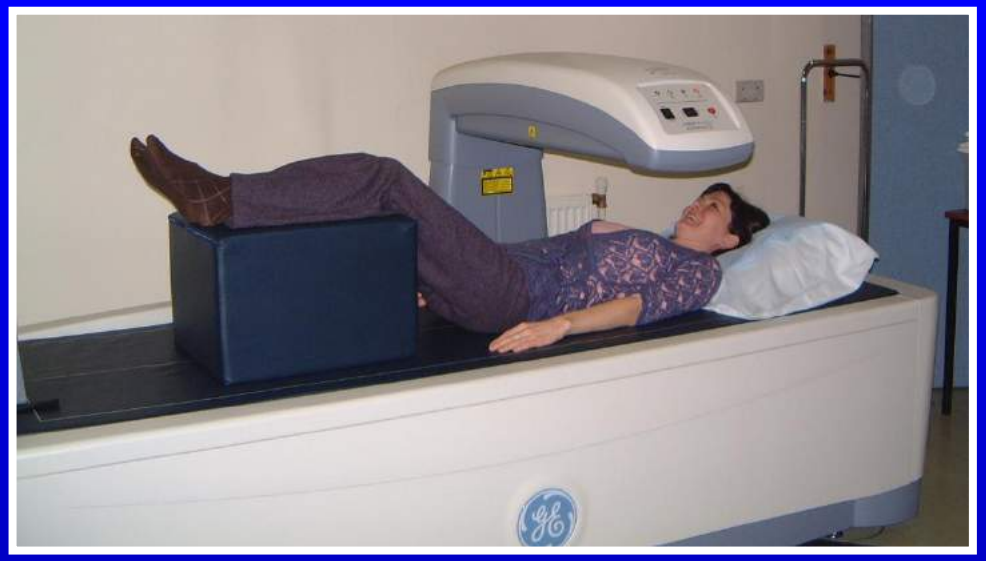

- Most widely available bone densitometry technique
- 40,000 + central DXA scanners world wide
- Central DXA (hip and spine) reference ('gold') standard for adult BMD osteoporosis definition- WHO T score ≤ -2.5
- DXA femoral neck optimum technique IN ADULTS for prediction of hip fracture

Improvement of DXA Image Quality

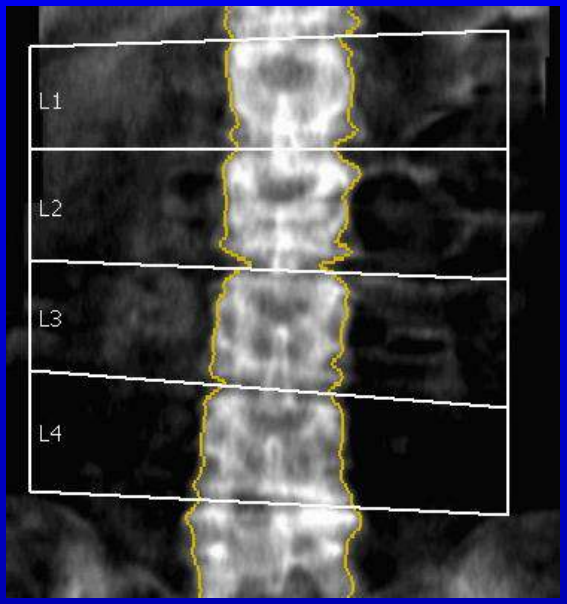

2009

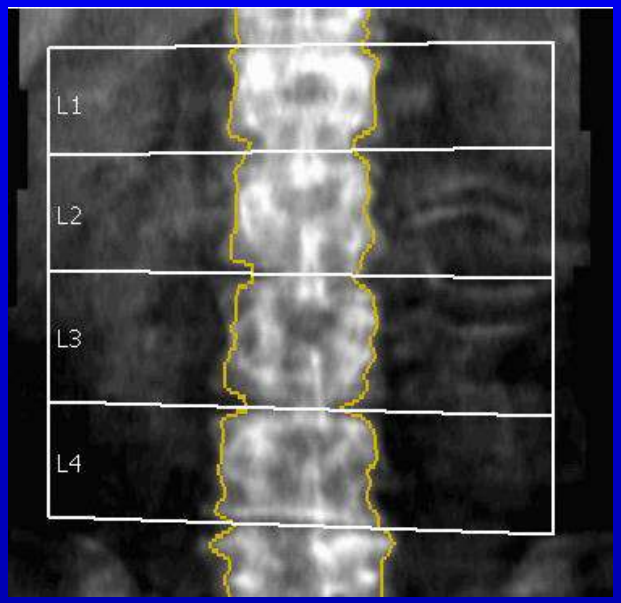

2010

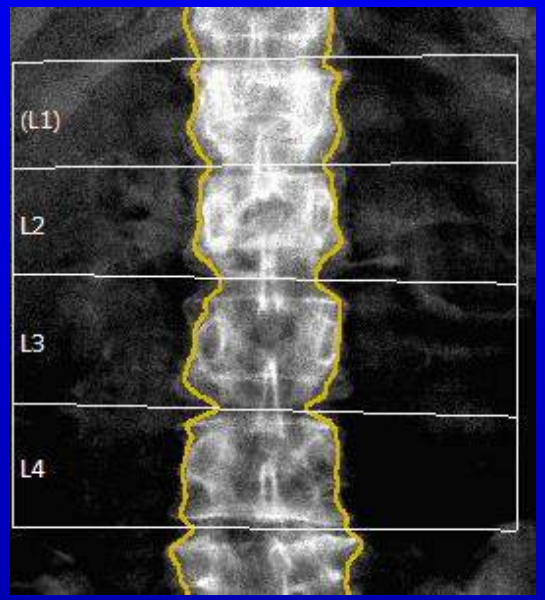

2013

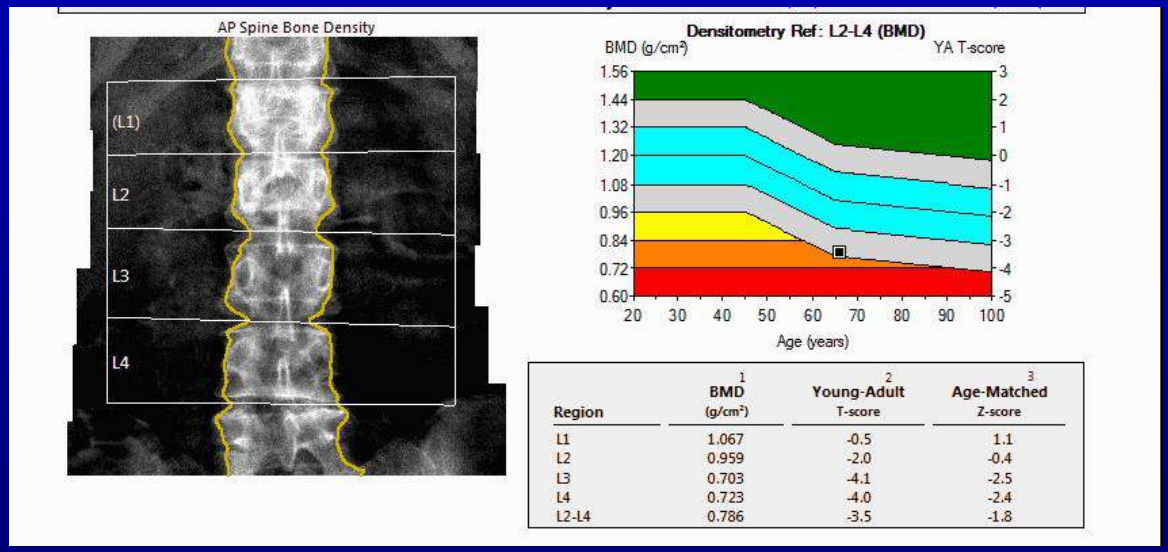

Region	1 BMD (g/cm²)	2 Young-Adult T-score	3 Age-Matched Z-score
L1	1.067	-0.5	1.1
L2	0.959	-2.0	-0.4
L3	0.703	-4.1	-2.5
L4	0.723	-4.0	-2.4
L2-L4	0.786	-3.5	-1.8

- Improved detectors
- Slightly higher exposure dose

Improvement of DXA Image Quality

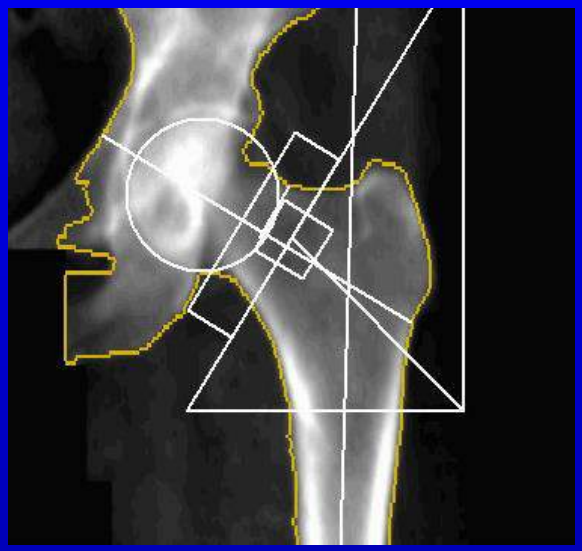

2009

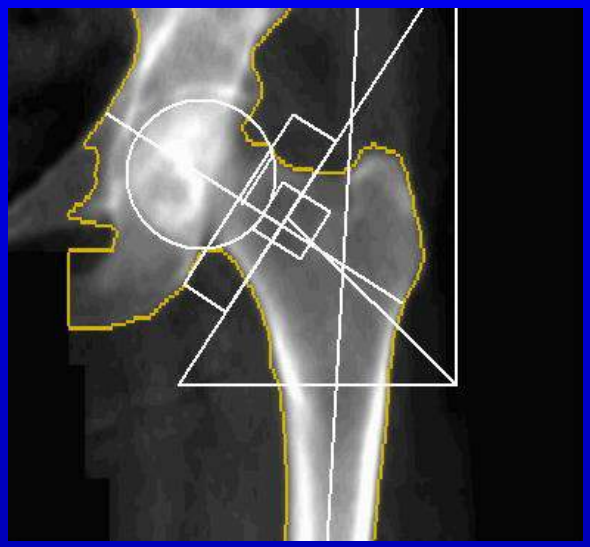

2010

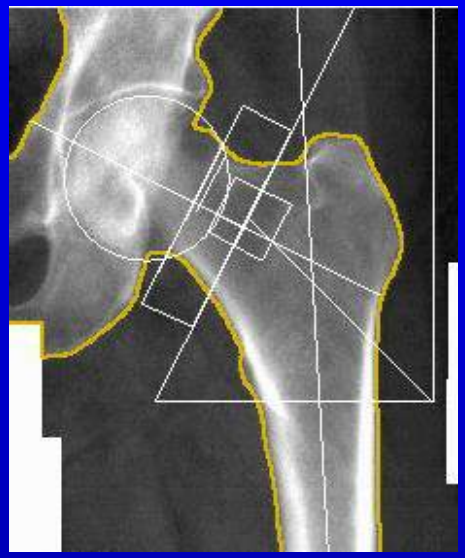

2013

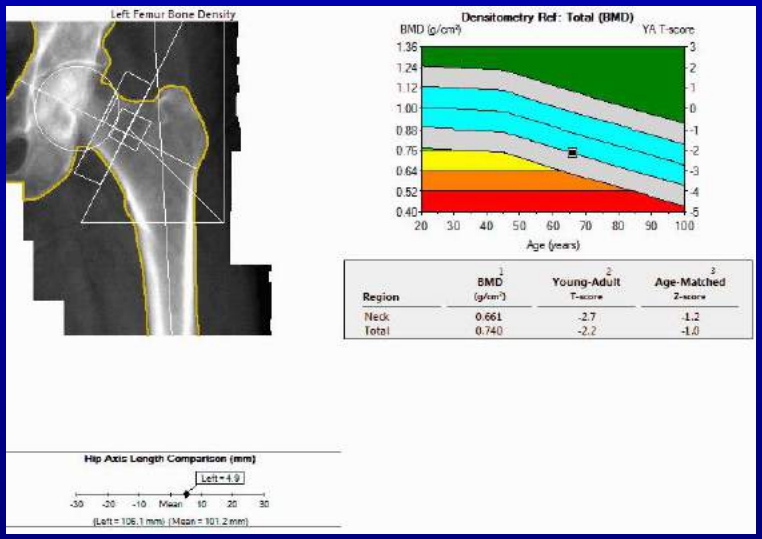

Images can be used for assessing:

- ❖ **Joint space**
- ❖ **OA grading**

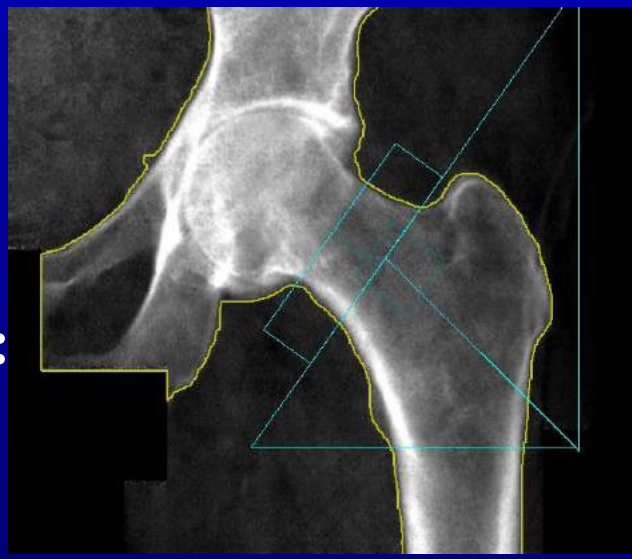

DXA

- PITFALLS - degenerative change, morphologic change, projected calcifications, elevated BMI… besides as it is an areal measurement it will overestimate the risk in persons with a small body frame.
- **Nearly half** of fragility fractures happen in **non osteoporotic individuals**, attending to DXA classification.
  Many clinical factors have been recognized as increasing the risk for fracture, independent of BMD.

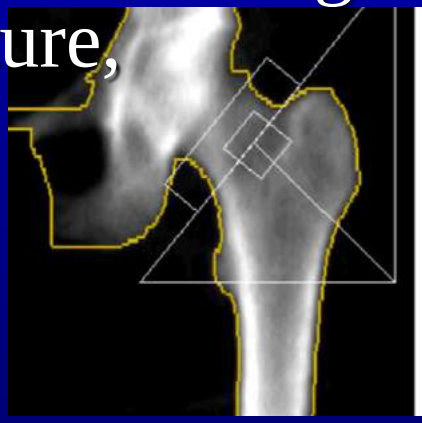

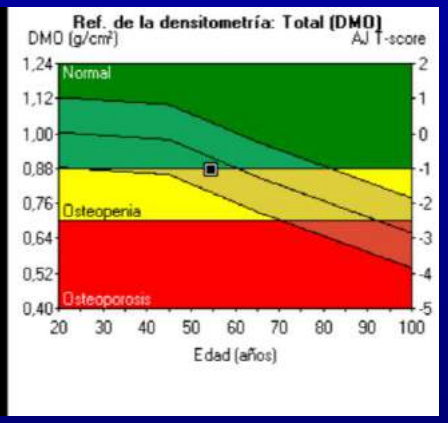

BONE STRENGTH = Quantity + Quality

- BONE QUANTITY – expressed as bone mineral density (BMD) - grams of mineral per area or per volume. It is determined by the peak bone mass and amount of bone loss.

- BONE QUALITY – refers to architecture, turnover, damage and accumulation and mineralization

NEW TECHNIQUES

Trabecular Bone Score (TBS)

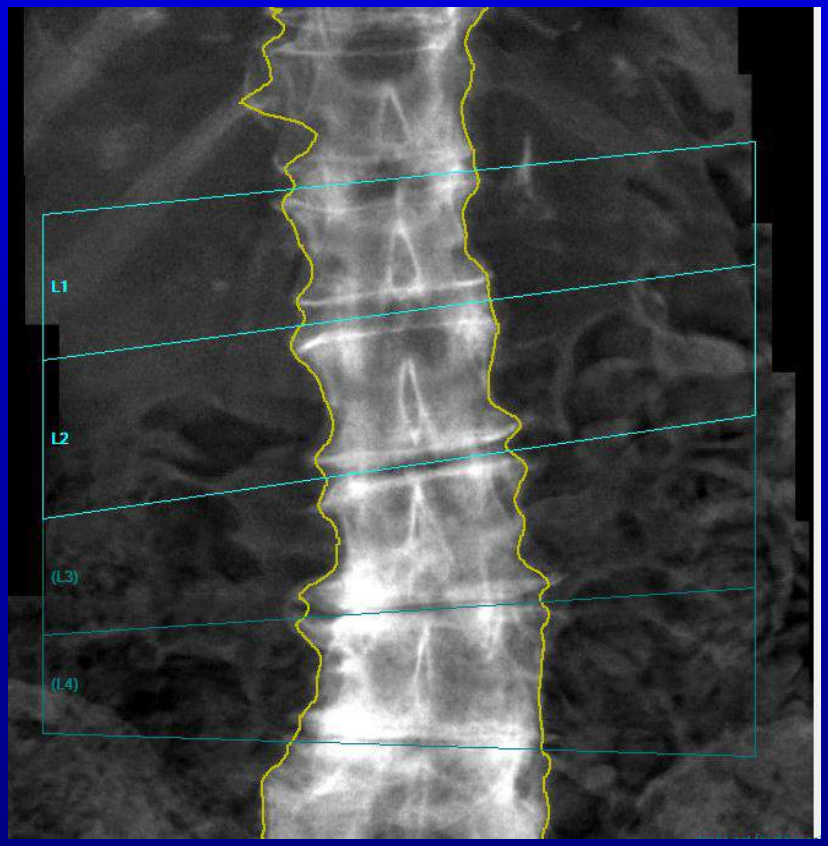

Trabecular bone score analysis has been introduced in the past 5 years to extract additional information from PA DXA scans of the lumbar spine. In this technique, a texture parameter is extracted from pixel grey-level variations in DXA images of the lumbar spine. The trabecular bone score is claimed to be a measure of trabecular structure.

Trabecular Bone Score (TBS) Process

TBS (Trabecular Bone Score) a new parameter: Principles



Healthy patient
Well structured trabecular bone

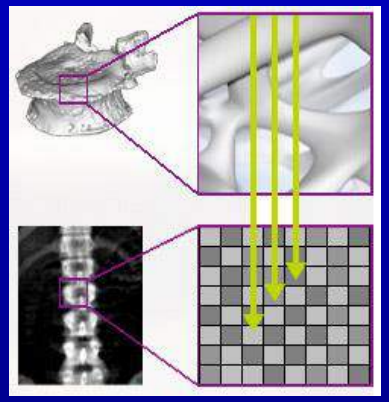

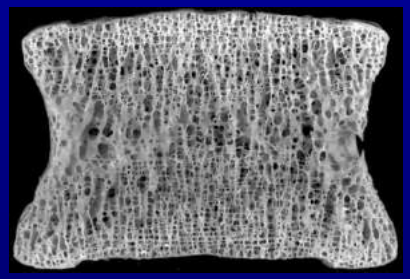

Osteoporotic patient
Altered trabecular bone structure

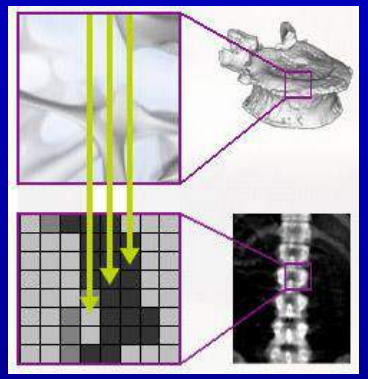

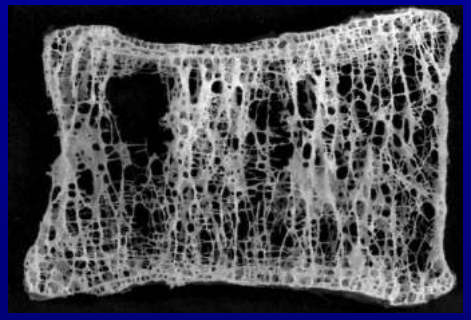

Good Microarchitecture

TBS = 1,360

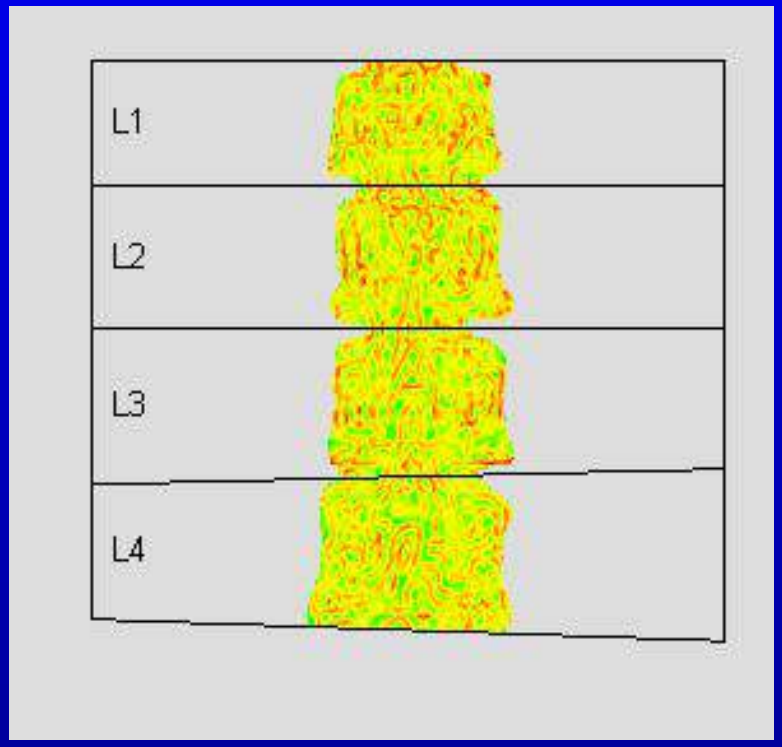

BMD= 0,652g/cm²

Poor Microarchitecture

TBS = 1,115

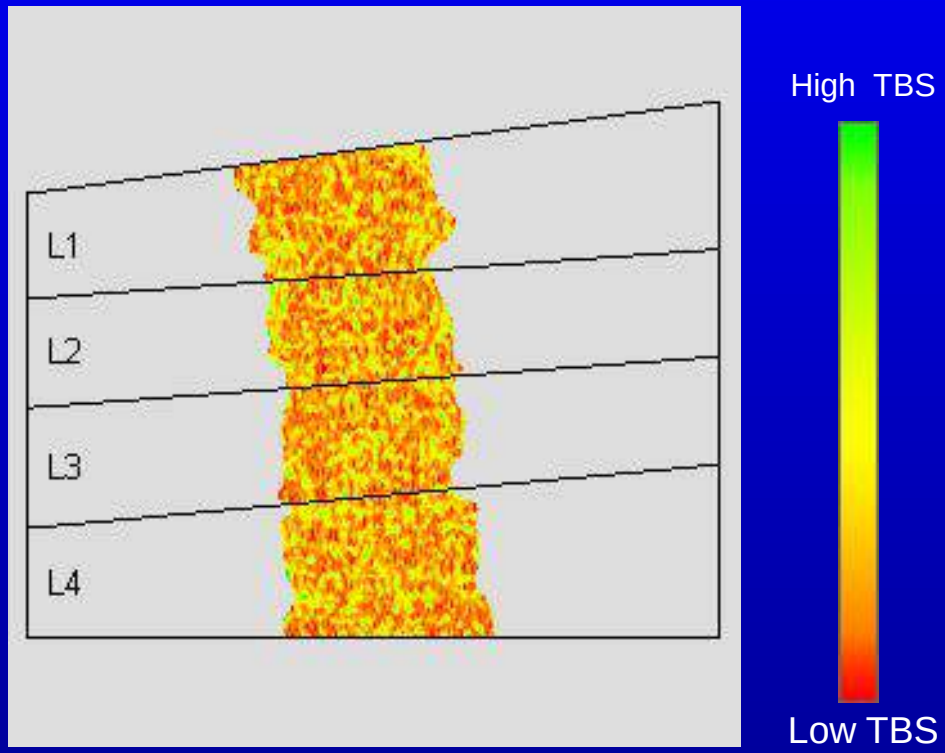

BMD = 0,659g/cm²

At equivalent BMD, TBS was displaying different values

TBS the assessment of bone micro-architecture in clinical practice

The Manitoba Prospective Study (29407 women)

When BMD alone is not enough, the combination of BMD + TBS enables to identify patients with high risk of fracture likely to have fractures whereas the patients are in the osteopenic zone

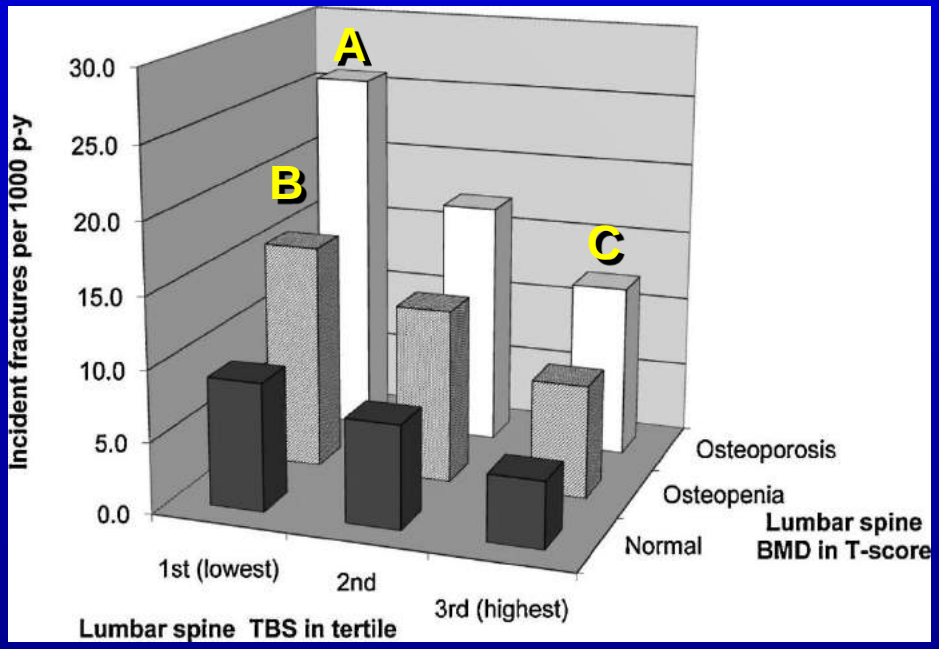

A: TBS identifies Osteoporotic patients as well as BMD

B-C: Osteopenic patients with a low TBS have a higher risk of fracture than osteoporotic patients with a normal TBS

TBS Diagnostic & Predictive capacity:
At same BMD the fracture risk is increasing when TBS is decreasing

TBS

2015 Adult Official Positions

- TBS is associated with vertebral, hip and major osteoporotic fracture risk in postmenopausal women.
- TBS is associated with hip fracture risk in men over the age of 50 years.
- TBS is associated with major osteoporotic fracture risk in men over the age of 50 years.
- TBS should not be used alone to determine treatment recommendations in clinical practice.
- TBS can be used in association with FRAX and BMD to adjust FRAX probability of fracture in postmenopausal women and older men.
- TBS is not useful for monitoring bisphosphonate treatment in postmenopausal women with osteoporosis.
- TBS is associated with major osteoporotic fracture risk in postmenopausal women with type II diabetes.

Quantitative Computed Tomography (QCT)

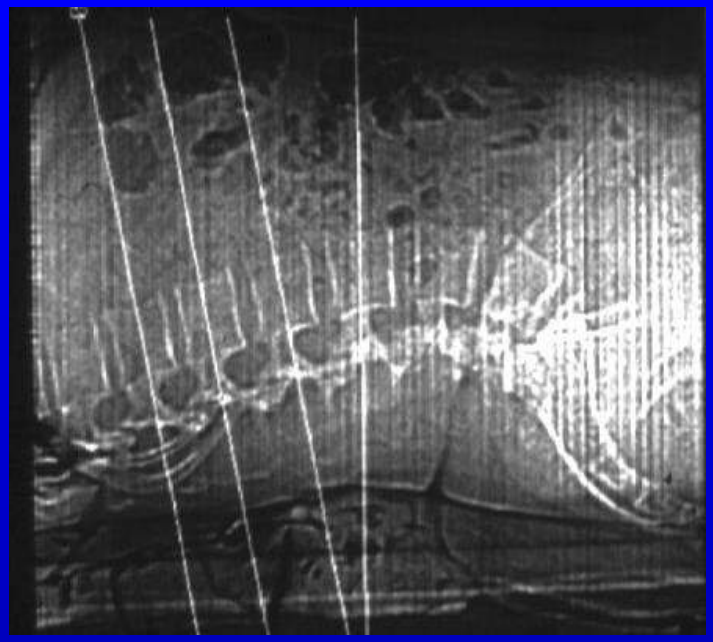

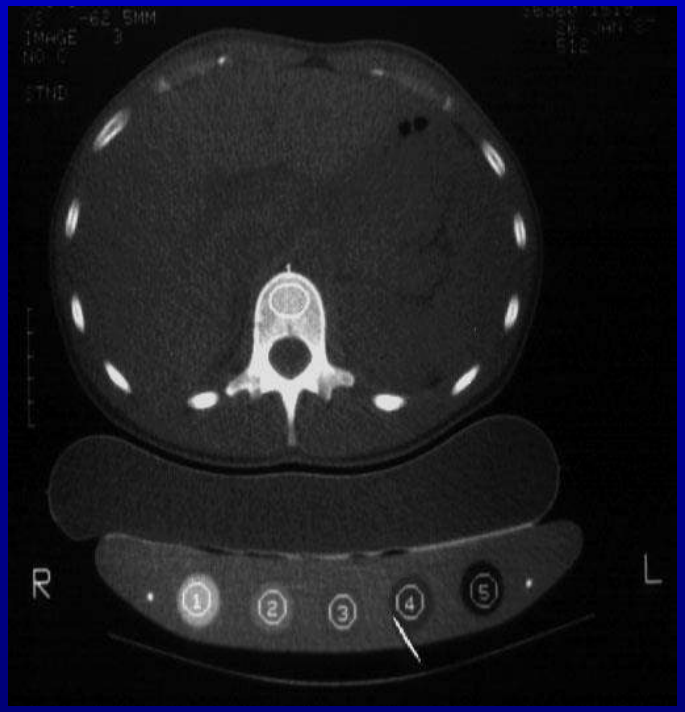

QCT

- True cross sectional 3-D method
- No soft tissue superimposition
- “true” BMD measurement (mg/cm^3)

Radiation doses

Examination	Site	EDE (µSv)	NBR	FC
DXA	Spine	**2.4 - 4**	**13 hours**	**<1 in few million**
	Femur	**2.4 – 5.4**	**20 hours**	**<1 in few million**
	Total body	**1.0– 3.4**	**11 hours**	**<1 in few million**
CT imaging	Abdo/pelvis	**10,000**	**4.5 years**	**1 in 2000**
3D-QCT	Spine	**55-100**	**10 days**	**1 in 200,000**
pQCT	Radius/ tibia	**0.43 per slice**	**1.7 hours**	**<1 in few million**
Radiograph	Hand	**<1**	**<1 hour**	**<1 in few million**
	Chest Lumbar spine	**20** **700-1000**	**3 days** **7 months**	**1 in I million** **1 in 200,000**
Return flight USA		**80**	**12 days**	**1 in 200,000**
Background radiation		**7-20 per day** **(2555-7300 per year)**		

EDE=effective dose equivalent; NBR=natural background radiation; FCR=Fatal cancer risk

Volumetric QCT

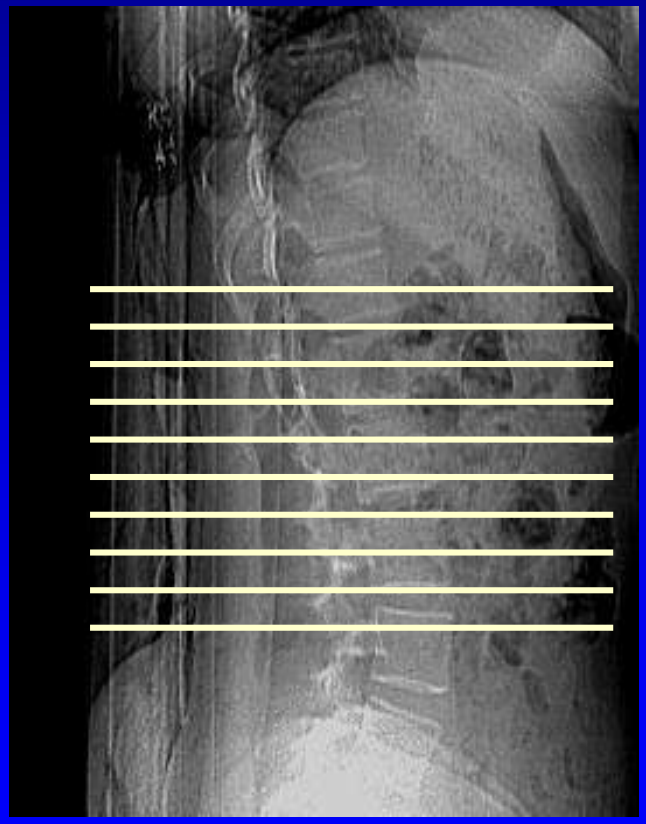

- L1-L3 or L1-L2
- contiguous 3 mm sections = 25-35 images over 8-12 cm volume
- No CT scanner gantry angulation
- Data acquisition <30-40 seconds

SPINE ANALYSIS

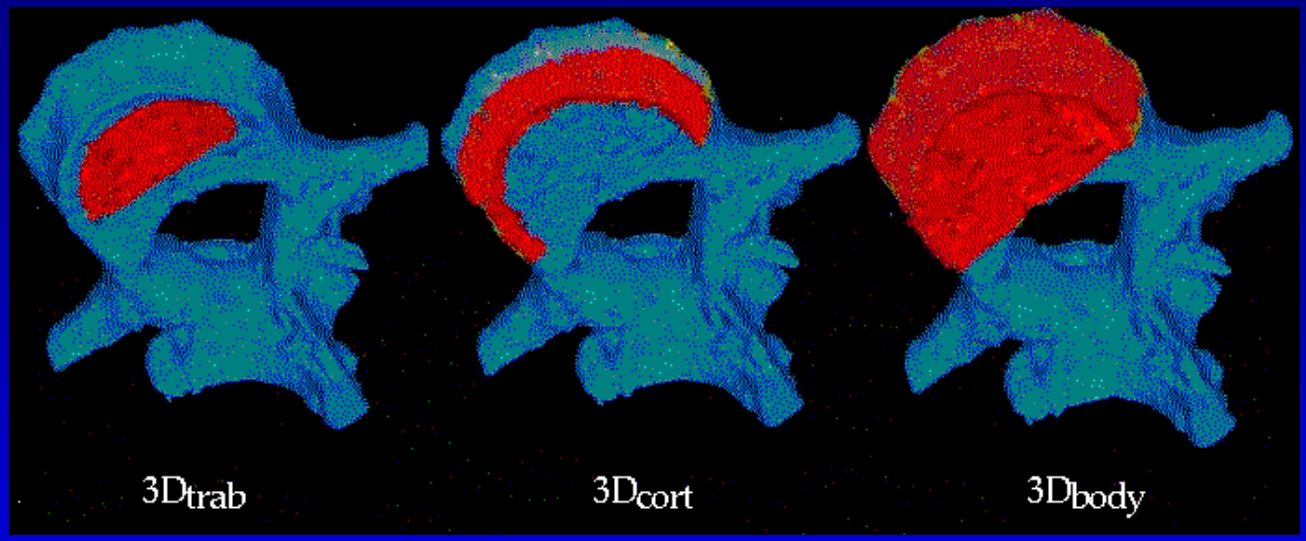



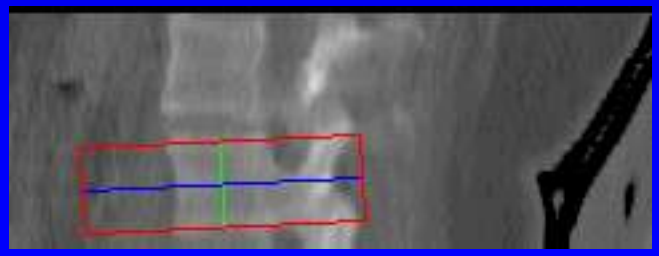

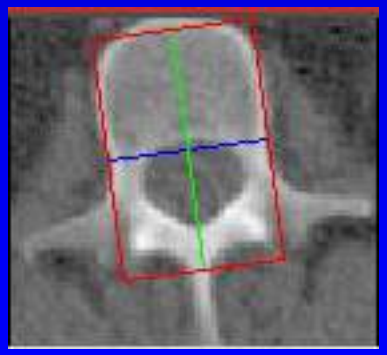

REGIONS OF INTEREST ALGORITHM HIP

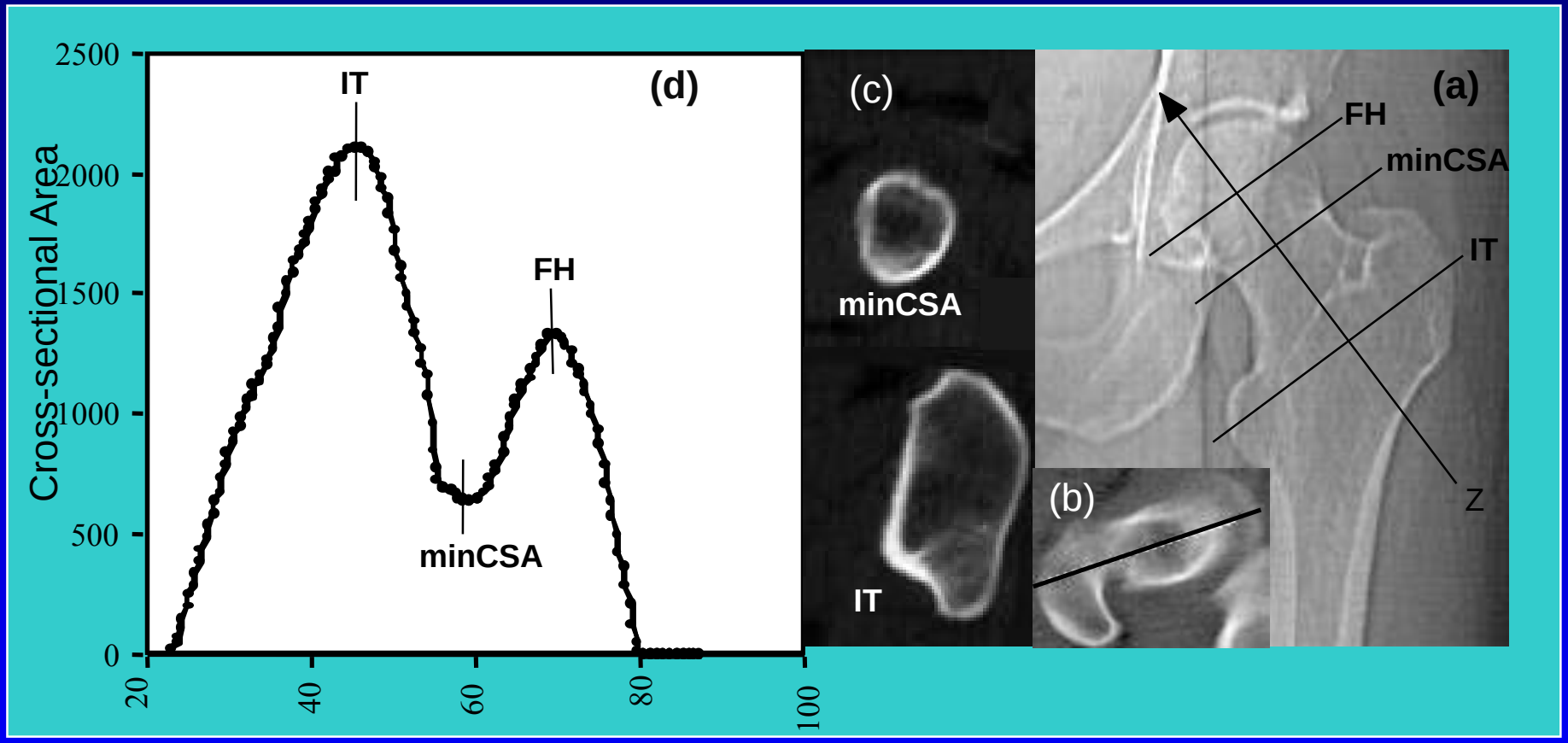

Analyze cross-sectional area of edge mask vs position on neck axis

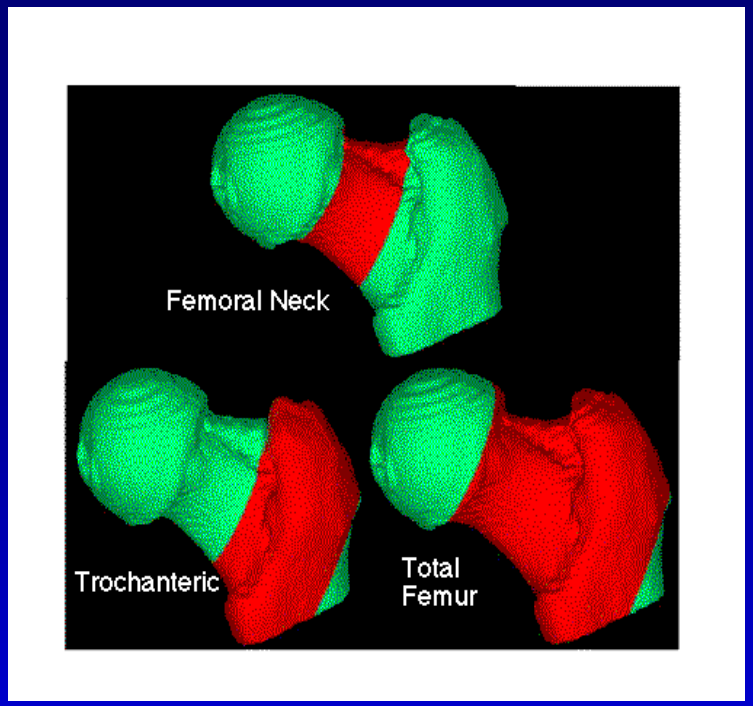
Femoral Neck
Trochanteric
Total
Femur

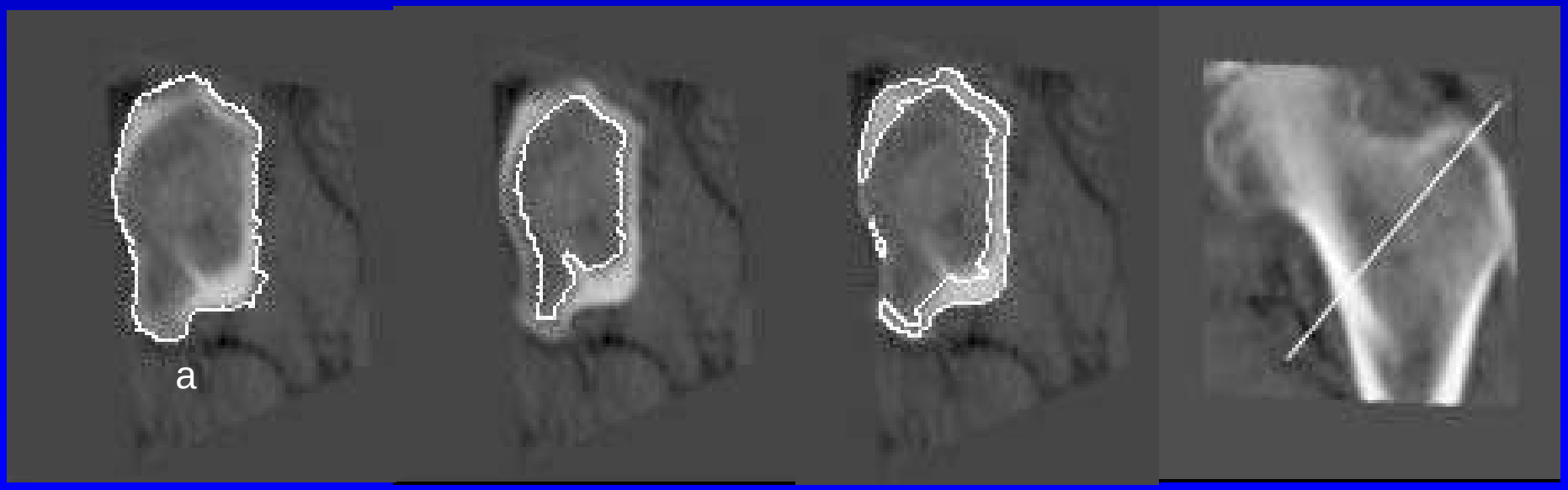
a

CT

ADVANTAGES:

- Volumetric technique – as opposed to areal DXA (independent of body size)
- Performed in any CT system (phantom) even MDCT. (Volumetric studies for hips)
- Separated estimation of trabecular and of cortical bone measurements – structural

Quantitative CT BMD

DISADVANTAGES:

- Higher dose of radiation, more than DXA
- Time consuming, especially compared to DXA.
- T-scores cannot be used given that with the adjustment a value of -2.5 would identify a much higher percentage of osteoporotic subjects. Absolute measurements are used instead of scores based on standard deviations
  - 110-80mg/cm^3 mild increase.
  - 80-50 mg/cm^3 moderate increase.
  - <50 mg/cm^3 severe increase.

HR PERIPHERAL QUANTITATIVE CT

ADVANTAGES:

- Higher signal-to-noise ratio than MDCT and MRI.
- BMD, trabecular, and cortical bone architecture information at the same time
- Radiation dose is lower when compared to whole body MDCT and besides this does not include radiosensitive organs.
- Possibility of using other software tools such as FEA.
- Very high reproducibility.

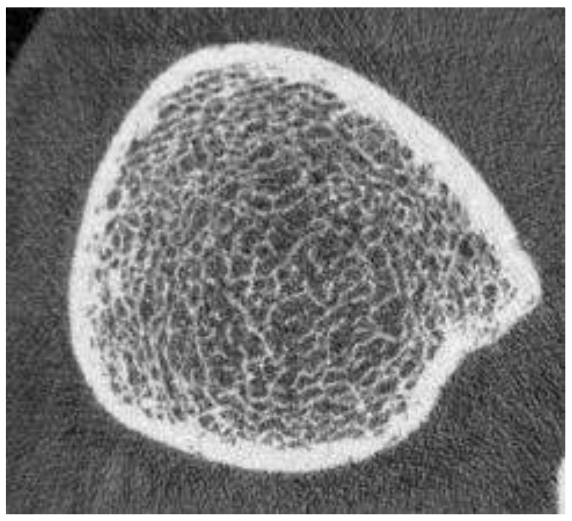

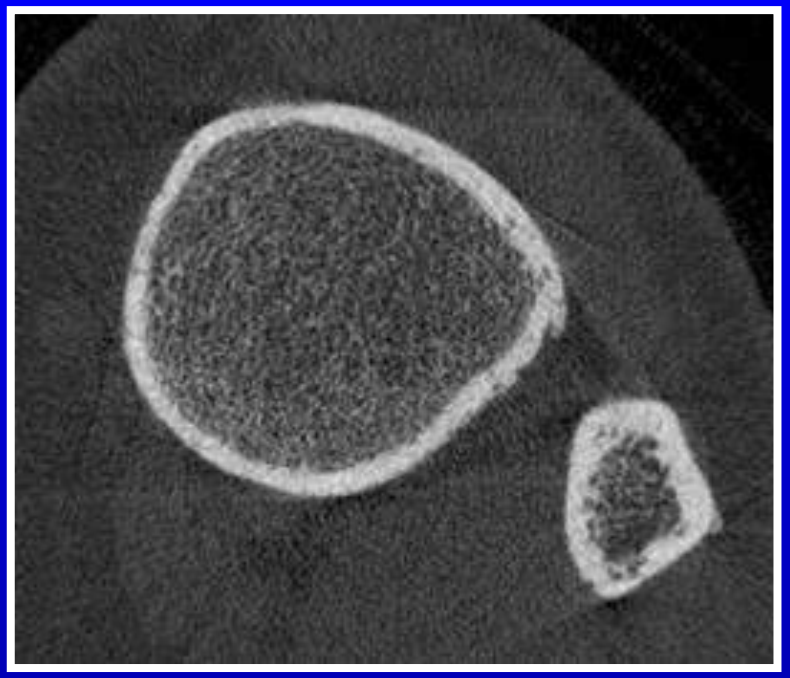

Normal

Cortical bone

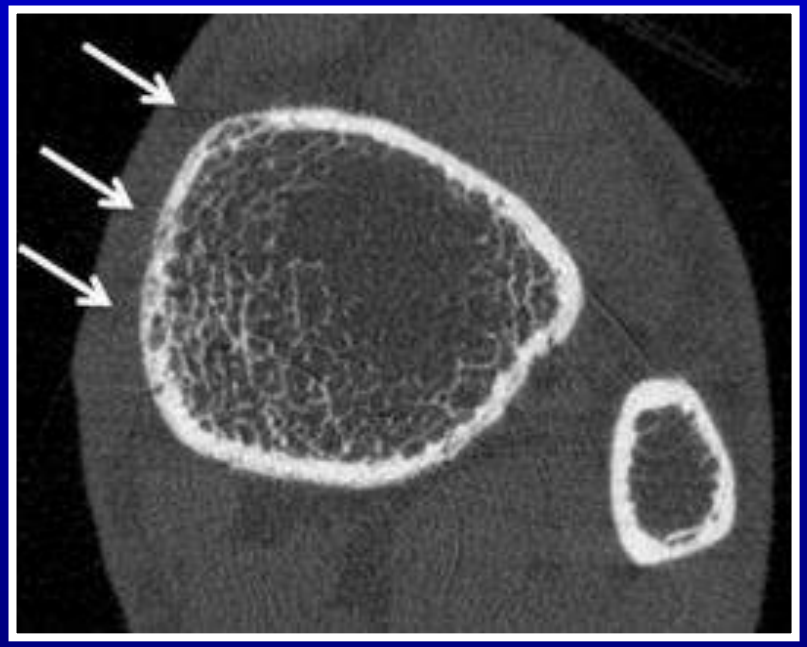

Postmenopausal 61yo woman, known fragility fracture.

Thomas M. Link, MD. *Radiology: Volume 26: number 1- April 2012*

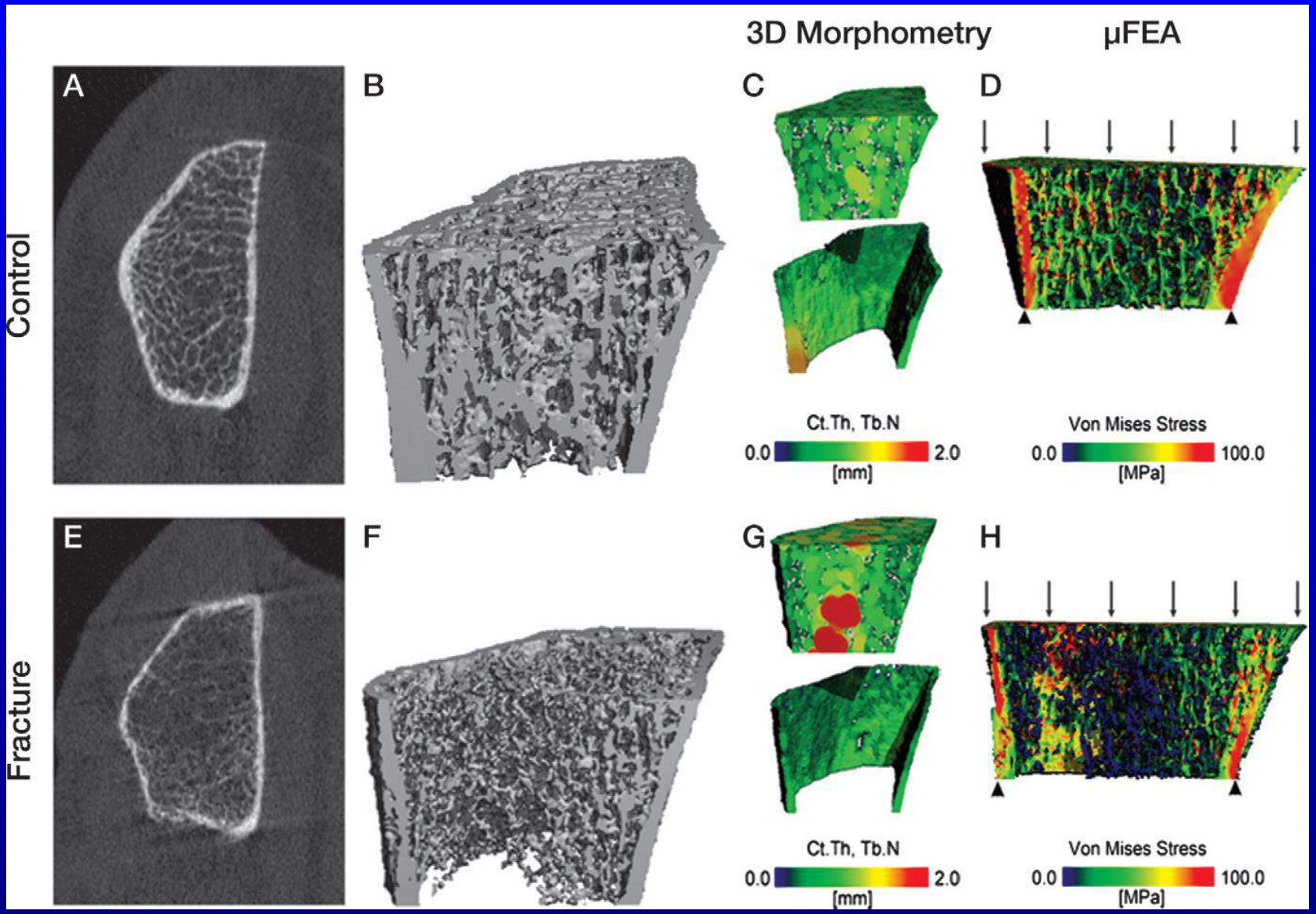
3D Morphometry
μFEA
Control
Fracture
A
B
C
D
E
F
G
H
Ct.Th, Tb.N
0.0
2.0
[mm]
Von Mises Stress
0.0
100.0
[MPa]

HR PERIPHERAL QUANTITATIVE CT

DISADVANTAGES:

- Limited to peripheral skeleton – no information on femur or spine (common sites for fragility fractures!)
- Expensive technique with a limited life span of the tube.
- Motion artifacts sometimes are limiting.

USES: studies – especially cortical

MRI

ADVANTAGES:

- Lack of radiation
- Ideal tool to study bone marrow
  - Proton MR spectroscopy allows us to quantify marrow adiposity
  - Bone marrow perfusion can be studied as well in dynamic contrast sequences
- Ultrashort echo time sequences (UTE) – cortical bone (renal osteodistrophy)

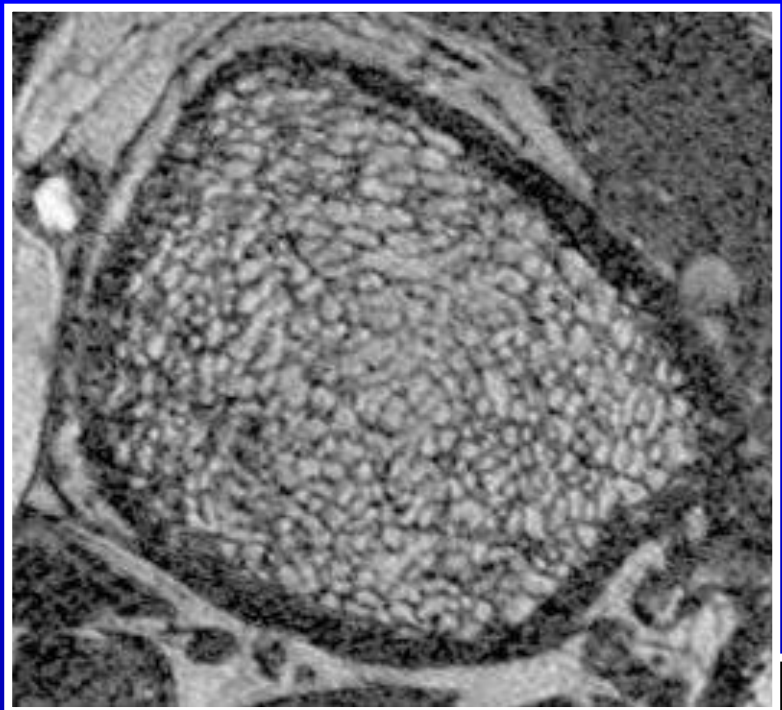

MRI

DISADVANTAGES:

- Limited resolution (trabecular size is very similar to the maximum resolution, resulting in partial volume effect).
- Acquisition time and in consequence motion artifacts.

USES: Longitudinal studies.

Bone marrow studies

Calculated T2* map

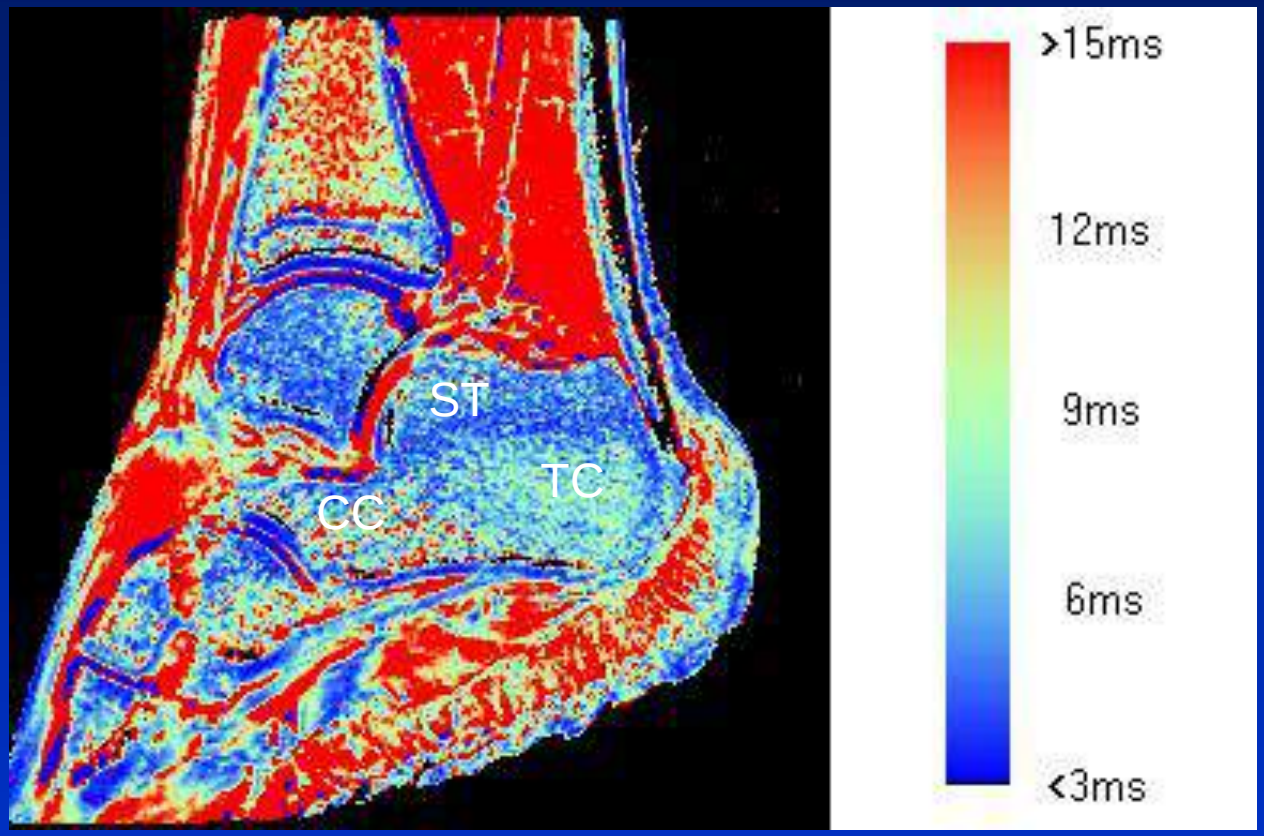

T2* map showing the examined calcaneal sites: cavum calcanei (CC), tuber calcanei (TC) and subtalar region (ST).

3D Radial Gradient-Echo (1.5 T)

- TE = 2.9 ms
- TR = 23.0 ms
- Acq. matrix = 512 × 512
- FOV = 100 mm
- Image resolution = 195 μm
- Slice thickness = 0.7 mm
- NSA = 2
- Synergy Flex-S coil

Advanced MR Imaging

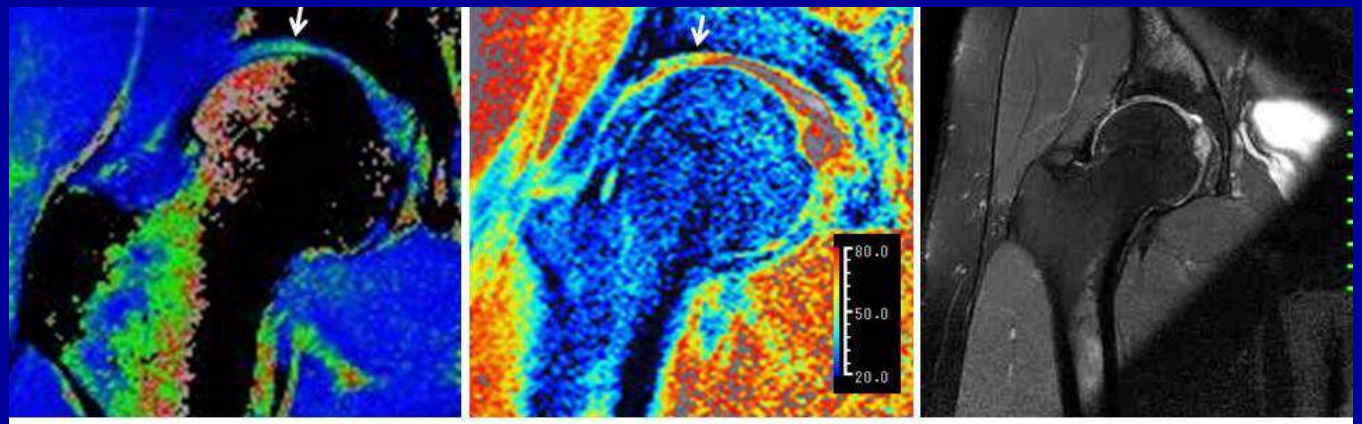

T1rho T2 mapping PDW

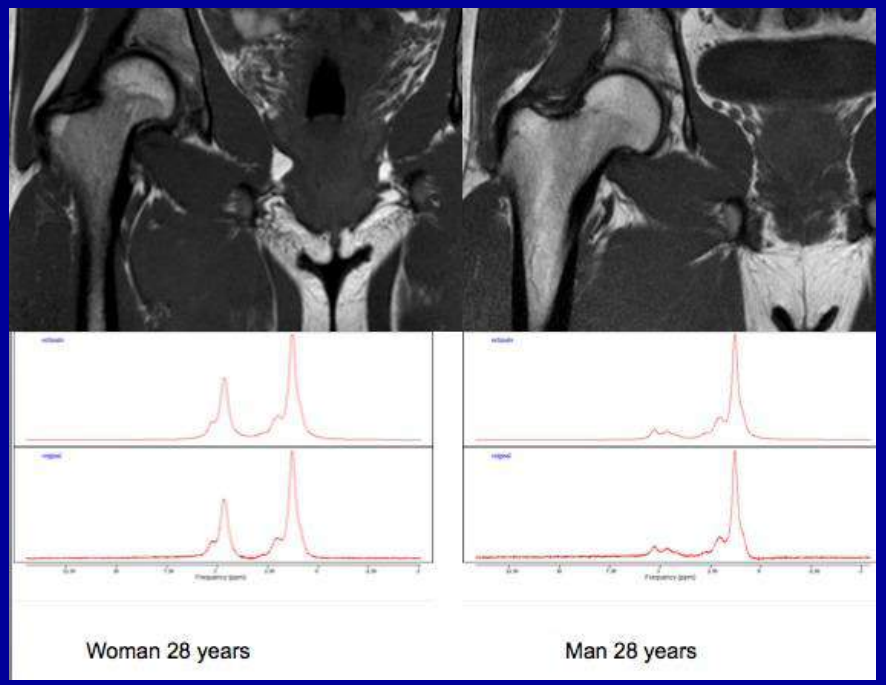

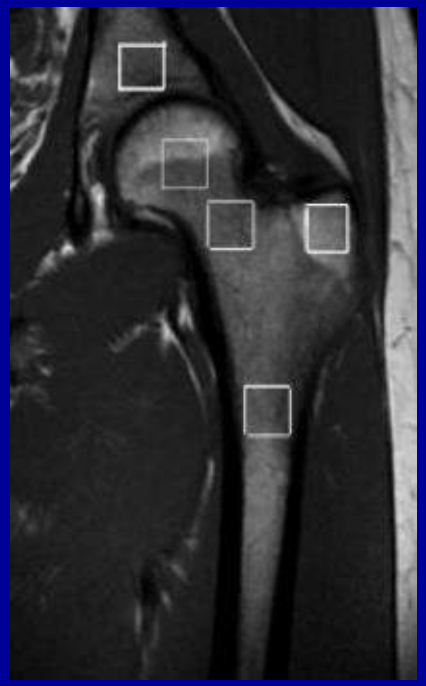

Proximal femur spectroscopy